



Near-fatal Fellatio: A Case of Necrotizing Fasciitis after Oral Sex

James J. Douglas^{1*}, Sherrill R. Brown¹, Andrew Martowski²
and W. David Hardy^{1,3}

¹Division of Infectious Diseases, Cedars-Sinai Medical Center, California.

²Department of Pathology, Cedars-Sinai Medical Center Cedars-Sinai, California.

³Department of Medicine, David Geffen School of Medicine, UCLA, Los Angeles, California.

Authors' contributions

This work was carried out in collaboration between all authors. All authors read and approved the final manuscript.

Case Study

Received 16th April 2014
Accepted 12th May 2014
Published 27th May 2014

ABSTRACT

A 35-year-old man was admitted to hospital 2 weeks after rough oral sex with *Streptococcus pyogenes* bacteremia, toxic shock syndrome and extensive necrotizing fasciitis of the abdominal and pelvic walls requiring debridement. His partner was diagnosed with strep throat shortly after their sexual encounter.

Keywords: Streptococcus pyogenes; necrotizing fasciitis; toxic shock syndrome; sexually transmitted disease.

1. INTRODUCTION

A 35-year-old man without significant medical history was admitted to the teaching service of Cedars-Sinai Medical Center complaining of 4 days of fever, chills, nausea, diarrhea, scrotal swelling and lower abdominal pain. Two weeks prior to admission, he noticed tender, peri-umbilical pustules with white discharge along with a non-tender sore on the base of his penis. He first noticed the lesion following a night of rough sex including prolonged fellatio with a female partner. He endorsed having multiple sexual partners and using condoms only

*Corresponding author: E-mail: josh.douglas1974@gmail.com;

occasionally. He did not use a condom during this episode and did not have any partners after this encounter.

In the Emergency Department, his oral temperature was 99.1 degrees Fahrenheit; blood pressure was 90/43mmHg and heart rate was 146 beats per minute. On physical exam, he was diaphoretic; his oropharynx was notable for mild erythema without exudate; his abdomen was markedly tender to palpation along the left lower quadrant extending laterally to his left flank; his skin was diffusely plethoric with increased erythema in all areas of acute tenderness. There were 3 small, dry, ulcerated lesions around his umbilicus. His scrotum and penis were profoundly edematous, erythematous and exquisitely tender to palpation.

His white blood cell count (WBC) was $8.7 \times 10^3/\mu\text{L}$ (reference range $4-11 \times 10^3/\mu\text{L}$) with a platelet count of $64 \times 10^3/\mu\text{L}$ (reference range $150-450 \times 10^3/\mu\text{L}$) (See Table 1). His sodium and calcium values were low at 123mg/dL (reference range 135-145mg/dL) and 7.1mg/dL (reference range 8.4-10.2mg/dL) respectively with a creatinine of 3.5mg/dL (reference range 0.4-1.2mg/dL). Computed tomography (CT) scan of his abdomen and pelvis revealed diffuse edema and stranding of the retroperitoneal tissue and mesentery including peri-nephric stranding along with diffuse edema involving the wall of the scrotum (See Fig. 1).

Table 1. Laboratory tests upon hospital admission

Test	Results	Reference range
White blood cells	$8.7 \times 10^3/\mu\text{L}$	$4.0-11.0 \times 10^3/\mu\text{L}$
Platelets	$64 \times 10^3/\mu\text{L}$	$150-450 \times 10^3/\mu\text{L}$
Sodium	123mg/dL	135-145mg/dL
Calcium	7.1mg/dL	8.4-10.2mg/dL
Creatinine	3.5mg/dL	0.4-1.2mg/dL

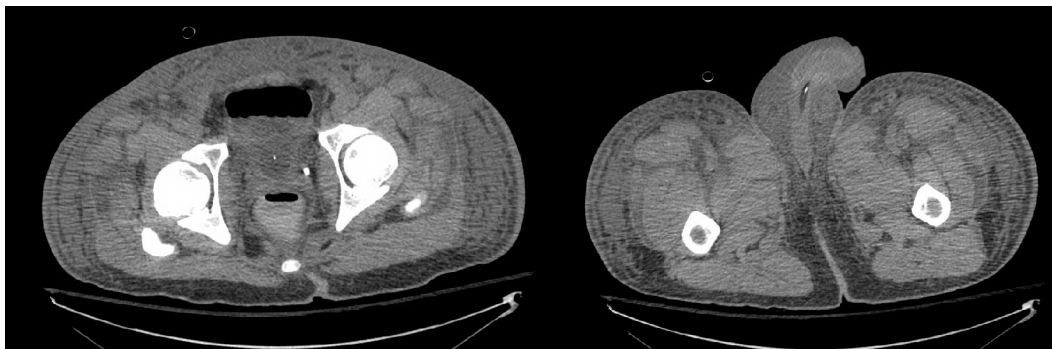


Fig. 1. Computed tomography of abdomen and pelvis showing diffuse subcutaneous edema, along with edema seen between the muscle bundles in the abdomen and pelvis, fluid in pelvis and significant scrotal edema

The patient was initially treated in the ICU due to concerns of probable sepsis. He was treated with vancomycin, piperacillin/tazobactam, doxycycline and clindamycin. Urgent surgical consultation was called for evaluation of possible Fournier's gangrene with necrotizing fasciitis. Initial surgical review did not judge his presentation to be consistent with necrotizing fasciitis. Medical management with intravenous antibiotics was continued. His temperature increased to 102.4 degrees Fahrenheit the next day; all four baseline blood

cultures grew *Streptococcus pyogenes*. His WBC increased to $23.4 \times 10^3/\mu\text{L}$. He received three doses (2gm/kg total) of intravenous immunoglobulin over the next 3 days for treatment of toxic shock syndrome. Both his temperature and WBC declined following this treatment.

Upon further questioning, the patient endorsed having had a sore throat just prior to his presentation to the ED. Of note, the woman who had given him prolonged fellatio two weeks ago had also been diagnosed with “strep throat” soon after their sexual encounter. On hospital day 7, he was transferred to the medical ward. Despite continued broad-spectrum antibiotic treatment, he continued to have intermittent fevers. His physical exam persistently revealed erythema and induration of the skin overlying and marked tenderness of his left lower abdomen extending to his supra-pubic area and around his scrotum. Due to the development of cutaneous anesthesia over his left lower abdomen, elevated WBC and fevers, he underwent a skin biopsy on hospital day 17. The biopsy revealed gram-positive cocci with suppurative inflammation consistent with necrotizing fasciitis (See Fig. 2). He underwent surgical debridement of his left lower abdominal wall extending to his scrotum. A wound vacuum was used for wound care; his antibiotics were de-escalated to intravenous ceftriaxone and oral metronidazole for 6 weeks following debridement, then 3 weeks of oral amoxicillin-clavulanate. His post-surgical course was complicated by chronic neuropathic pain involving the surface of his left lower abdomen and post-surgical scarring. Of note, he reports resolution of all genital abnormalities and return of previous normal sexual functioning.

Streptococci are gram-positive, catalase-negative, oval or coccoid-shaped bacteria that arrange in pairs and chains when stained by Gram’s method. They ferment glucose to lactic acid without the production of gas and grow both aerobically and anaerobically. Group A beta-hemolytic streptococci (GAS), best represented by *Streptococcus pyogenes*, the father figure of the species is responsible for many common clinical manifestations including pharyngitis, upper and lower respiratory tract, skin and soft tissue infections with a number of nonsuppurative sequelae.

GAS are infrequently isolated from the skin perhaps due to the fact that *In vitro* studies have shown that unsaturated fatty acids extracted from normal human skin are bactericidal for streptococci. However, skin colonization can often predict development of subsequent infection. In a prospective study involving children diagnosed with GAS respiratory infections, the disease-causing streptococcal strain was recovered from 94% of the children’s uninfected skin before it appeared in the respiratory tract (mean of 14 days for sinusitis and 20 days for pharyngitis). In 74% of cases, respiratory tract lesions harboring this specific strain developed 10 days after skin acquisition [1]. Although GAS is an infrequent skin colonizer, it is the most frequently isolated pathogen from prepubertal girls presenting with vulvovaginitis, with one study showing a 59% culture positive rate among cases [2]. Peak incidence of these GAS infections occurred during winter in one study concurrent with increased incidence of Streptococcal pharyngitis. In another study, GAS infections occurred year-round reflecting co-occurrence with summertime increases of impetigo [2,3]. These bacteria may be spread from the skin contiguously, from the GI tract directly or from the respiratory tract by the hands. One study of female pediatric patients being treated for streptococcal infections found that 10%-15% had vaginal infections with the same strain present in the throat [4]. Among adult women, GAS vaginal colonization remains extremely low. In one study of 6944 vaginal and rectal swab samples obtained from all patients delivering infants at a Vermont hospital during a 38-month period showed a 20.1% colonization rate for group B streptococcus but only a 0.03% colonization rate for GAS [5]. In the largest study to date, 3430 vaginal or vulvar cultures from patients with vulvovaginitis,

group A streptococcus was isolated from nearly 20% of children but just over 1% of women of childbearing age [3]. This difference between prepubertal and postpubertal females may be in part explained by the vaginal colonization with lactobacilli in postpubertal females that metabolizes glucose to lactate which is responsible for the normal vaginal pH of 3.5 to 4.6. An absence of *Lactobacilli spp.* and subsequent increase in vaginal pH is well-documented to occur during episodes of bacterial vaginosis and can include other catalase-negative pathogens.

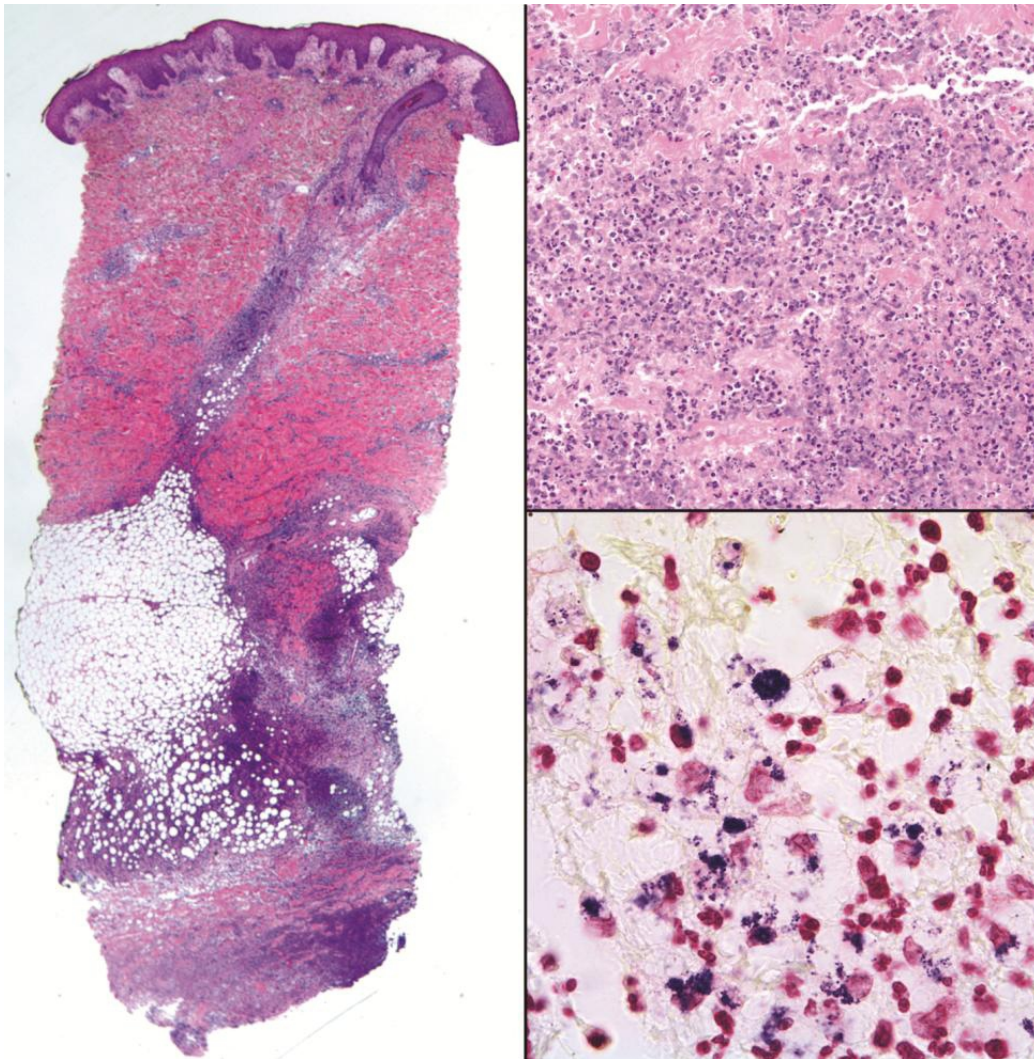


Fig. 2. Punch biopsy of abdominal wall. (2A) scanning magnification showing severe, deep inflammation involving the subcutaneous fascia (H&E). (2B) necrotizing, suppurative inflammation (H&E). (2C) abundant gram-positive cocci in clusters and chains (Gram)

Case reports exist with anal, vaginal or perineal colonization as likely sources for invasive streptococcal disease including pyodermas, scarlet fever, perineal cellulitis and pharyngitis

[6-9]. Sobel et al. described two cases of GAS vulvovaginitis in adult women whose husbands were anal carriers of GAS [10]. Furthermore, GAS invasive skin and soft tissue disease has been documented in pelvic surgery possibly reflecting skin, gastrointestinal (GI) or genitourinary (GU) colonization. Mechanisms for how GAS colonize the GI or GU tract remain a mystery, but most likely patients or their close contacts have some element of skin, pharyngeal or GI colonization. Vulvar necrotizing fasciitis is a well-described complication of surgical incisions including peripartum wounds, minor trauma, vulvar abscesses and Bartholin's gland abscesses. The prevalence of diabetes mellitus among women with these infections in one study was 69%--the single highest risk factor for mortality [11,12]. Balanoposthitis (infection of the glans penis and foreskin) caused by GAS is also well documented. Most cases involve uncircumcised children presenting with balanitis likely secondary to poor penile hygiene and autoinoculation from other sites. In one study from Japan, 47 of 189 (25%) penile cultures from adult males presenting with balanoposthitis grew GAS. The route of inoculation was predominantly sexual (78.7%) with the majority of patients reporting fellatio from a commercial sex worker [13]. One case report documented the development of Fournier's gangrene of the penis in a male after sustaining an abrasion during oral sex with a commercial sex worker [14]. The high prevalence of streptococcal skin and soft tissue infections in patients with precipitating conditions such as penetrating injuries, minor cuts, burns, splinters, surgical procedures, childbirth, blunt trauma, muscle strain especially among those with immune compromising states including diabetes mellitus, cirrhosis and non-steroidal anti-inflammatory drug (NSAIDs) use is clearly understood [1]. Although bacterial serotyping was not performed between the isolates isolated from our patient and his sexual partner, it is highly probable that the origin of the GAS causing necrotizing fasciitis originated in his partner's oropharynx and was inoculated during oral sex with minor penile trauma. Reports suggest that streptococcal strains of M protein types 1, 3, 12, and 28 are most commonly involved and, in the United States, usually elaborate pyrogenic exotoxin A.

This case, once again, reinforces the critical importance of physicians taking a thorough and detailed sexual history as well as being cognizant not only of the manifestations of typical sexually acquired infections but also of less common, but potentially life-threatening infections transmitted by sexual contact. This case provides substantial evidence to support that *S. pyogenes* should be considered, along with other pathogens when approaching a patient with a possible sexually transmitted disease.

2. CONCLUSION

A 35-year-old man was admitted to hospital 2 weeks after rough oral sex with *Streptococcus pyogenes* bacteremia, toxic shock syndrome and extensive necrotizing fasciitis of the abdominal and pelvic walls requiring debridement. His partner was diagnosed with strep throat shortly after their sexual encounter.

CONSENT

Patient provided written consent for this case report.

ETHICAL APPROVAL

Authors obtained ethical approval from Cedars-Sinai Medical Center.

COMPETING INTERESTS

Authors have declared that no competing interests exist.

REFERENCES

1. Ferrieri P, Dajani AS, Wannamaker LW, Chapman SS. Natural history 162 of impetigo. I. Site sequence of acquisition and familial patterns of spread of cutaneous streptococci. *J Clin Invest.* 1972;51(11):2851-62.
2. Stricker T, Navratil F, Sennhauser FH. Vulvovaginitis in prepubertal girls. *Arch Dis Child.* 2003;88:324-6.
3. Morris CA. Seasonal variation of streptococcal vulvo-vaginitis in an urban community. *J Clin Pathol.* 1971;24:805-7.
4. Hedlund P. Acute vulvovaginitis in streptococcal infections. *Acta Paediat.* 1953;42:388-9.
5. Mead PB, Winn WC. Vaginal-rectal colonization with group a streptococci in late pregnancy. *Infect Dis Obstet Gynecol.* 2000;8(5-6):217-9.
6. McKee WM, Di Caprio JM, Roberts CE Jr, Sherris JC. Anal carriage as the probable source of a streptococcal epidemic. *Lancet.* 1966;2:1007-9.
7. Stamm WE, Feeley JC, Facklam RR. Wound infections due to group a streptococcus traced to a vaginal carrier. *J Infect Dis.* 1978;138:287-92.
8. Tonkovic-Capin V, Fleming MG, Kleven-Kranz K, Lund MR. Vulvovaginitis and perineal cellulitis due to group a streptococcus in an adult woman. *Arch Dermatol.* 2005;141(6):790-2.
9. Richman DD, Breton SJ, Goldman DA. Scarlet fever and group a streptococcal surgical wound infection traced to an anal carrier. *J Pediatr.* 1977;90:387-90.
10. Sobel JD, Funaro D, Kaplan EL. Recurrent group a streptococcal vulvovaginitis in adult women: family epidemiology. *Clin Infect Dis.* 2007;44(5):e43-5.
11. Stephenson H, et al. Necrotizing fasciitis of the vulva. *Am J Obstet .182 Gynecol.* 1992;166:1324-1327.
12. Addison W, et al. Necrotizing fasciitis of vulvar origin in diabetic patients. *Obstet Gynecol.* 1984;63:473.
13. Wakatsuki A. Clinical experience of streptococcal balanoposthitis in 47 healthy adult males. *Hinyokika Kyo.* 2005;51:737-774.
14. Anchi T, Tamura K, Inoue K, Ashida S, Yasuda M, Kataoka S, Saito K, Kuriyama M, Hiroi M, Sasaguri S, Shuin T. [Localized Fournier's gangrene of the penis: A case report]. *Hinyokika Kyo.* 2009;55(3):153-6.

© 2014 Douglas et al.; This is an Open Access article distributed under the terms of the Creative Commons Attribution License (<http://creativecommons.org/licenses/by/3.0>), which permits unrestricted use, distribution, and reproduction in any medium, provided the original work is properly cited.

Peer-review history:

The peer review history for this paper can be accessed here:
<http://www.sciencedomain.org/review-history.php?iid=495&id=27&aid=4714>