



## **Indigestible Plastic Bags are Hindering Profitability of Dairy Production in Peri-Urban Kampala**

**Dickson Stuart Tayebwa<sup>1,2\*</sup>, Rodney Okwasiimire<sup>1</sup>, Christine Kesiime<sup>1</sup>,  
Esther Nansubuga<sup>1</sup>, Steven Kakooza<sup>1,3</sup>, Mariam Komugisha<sup>4</sup>,  
Ismail Asiimwe<sup>5</sup> and Paul Ssuna<sup>1</sup>**

<sup>1</sup>Central Diagnostic Laboratory, College of Veterinary Medicine, Animal Resources and Biosecurity, P.O.Box 7062, Kampala, Uganda.

<sup>2</sup>Research Center for Tropical Diseases and Vector Control, College of Veterinary Medicine, Animal Resources and Biosecurity, P.O.Box 7062, Kampala, Uganda.

<sup>3</sup>Novel Minds Science Plexus, P.O.Box 7062, Kampala, Uganda.

<sup>4</sup>Department of Animal Health, Zonal Veterinary Inspector for Central Region, Ministry of Agriculture, Animal Industry and Fisheries, P.O.Box 513, Entebbe, Uganda.

<sup>5</sup>Infectious Diseases Institute, College of Health Sciences, Makerere University, P.O.Box 22418, Kampala, Uganda.

### **Authors' contributions**

*This work was carried out in collaboration between all authors. All authors read and approved the final manuscript.*

### **Article Information**

DOI: 10.9734/CJAST/2019/v32i630037

#### Editor(s):

(1) Dr. Wen Shyang Chow, Professor, School of Materials and Mineral Resources Engineering, Engineering Campus, Universiti Sains Malaysia, Malaysia.

#### Reviewers:

(1) El Mahdy Cristina, University of Agricultural Sciences and Veterinary Medicine Cluj-Napoca, România.

(2) Kamran Baseer Achakzai, Livestock & Dairy Development Department Balochistan, Pakistan.

Complete Peer review History: <http://www.sdiarticle3.com/review-history/46844>

**Short Communication**

**Received 09 November 2018**

**Accepted 22 January 2019**

**Published 22 February 2019**

### **ABSTRACT**

Many Ugandans living in the urban and peri-urban areas have started dairy farming to tap into the demand for milk and its products, driven by the population growth. Unfortunately, they operate on a small scale because land and cattle feeds in the urban and peri-urban areas are limited. In addition, the peri-urban areas are contaminated with indigestible materials such as plastic bags which once consumed by the cattle impair health, cause loss of milk productivity and death. This report documents the findings from three cases referred to the ambulatory clinic at the Central

\*Corresponding author: E-mail: [tayebwa.dickson@gmail.com](mailto:tayebwa.dickson@gmail.com);

Diagnostic Laboratory (CDL) in 2018. The cases were diagnosed as hardware disease and surgically treated by rumenotomy. In addition, a review of the patients' data sheets in CDL was performed to identify other cases of hardware disease documented in 2018. Both metallic and non-metallic indigestible materials were recovered from the rumen and reticulum of the three animals operated. The indigestible foreign materials included nails, wire, plastic bags and a sisal rope. The common clinical signs coherent with the presence of indigestible materials were chronic emaciation and loss of appetite. The review of the patients' data sheets showed that blood samples of 23 cases of suspected hardware disease were submitted to CDL in 2018 for diagnosis. It is paramount that farmers are sensitized about the effects of indigestible materials on the production of dairy animals. For, such an intervention would liberate the peri-urban dairy farmers from losses attributed to hardware disease.

*Keywords: Hardware disease; Ingested plastic bags; Peri-urban dairy farming; Uganda.*

## 1. INTRODUCTION

Hardware disease is a dreaded disorder of cattle and other ruminants that occurs primarily as a result of the ruminant's inability to select feed during prehension [1]. Hence, ruminants will inadvertently swallow any indigestible materials availed within the feeds. Following the ingestion, the effects vary depending on the type of material and localization within the ruminants' fore stomachs [2]. Sharp objects such as nails and wires are hurtful because they can pierce the wall of the esophagus causing trauma and pain during swallowing [3,4]. Once ingested, the metallic objects often lodge in the reticulum. In adverse circumstances, the wire or nail penetrates the wall of the reticulum and pericardium causing *peritonitis*, *pericarditis*, *pleuritis* and death. On the other hand, partial penetration into the wall of the reticulum may occur resulting into wall thickening, fibrin deposition and indigestion. Invariably, the effects following ingestion of non-metallic materials manifest after a prolonged period of time, after they have accumulated. Up to 55 kg have been surgically recovered from the cattle rumen [1]. Of which the most commonly recovered non-metallic indigestible materials include plastic bags, ropes and cloths [1]. The sequelae for consumption of non-metallic foreign material include reduced feed intake, bloat, rumen impaction, nutritional deficiencies and deprivation [3]. Since the buildup may take weeks to months; at the time of diagnosis, the prognosis of such an animal is guarded.

The diagnosis of hardware disease is rather complex because it relies more on the clinical history and observation rather than laboratory diagnosis [4–6]. Although the use of radiography and ultrasonography eases the clinician's duty, non-metallic materials are hardly detectable [7,8].

On a lighter note, the diagnosis of hardware disease involving metallic objects is easier because the cardinal signs are easily detectable. These include arching of the back, groaning, abnormal gait and intolerance to locomotion, which are easy to observe [9].

One could say that hardware disease affects cattle reared under intensive management systems such as zero grazing and feedlot [1]. This accrues from the fact that feeds for intensively managed cattle undergo various steps of harvest, processing and storage which exposes them to indigestible foreign materials. This is even much more likely for poor nations because the feeds utilized are the locally available crop residues derived from food processing in homesteads and market places [10]. In addition, the cattle are supplemented with cut and carry pasture from nearby unconstructed plots or swamps, brewers waste, hay and silage.

Although this system is perfect for the land-constrained peri-urban farmers, daunting challenges that include low-grade feeds, animal welfare concerns and diseases such as laminitis, infertility and hardware disease accompany this type of system [11]. Previous studies [11–13] have reported on infertility and managerial constraints. However, hardware disease remained neglected despite being a very serious problem to the farmers in Uganda. Therefore this article is the first to document the occurrence of hardware disease and point out its implications on dairy production in Uganda.

## 2. MATERIALS AND METHODS

### 2.1 Cases Description

All the cases involved in this report were referred to the ambulatory clinic at Central Diagnostic Laboratory (CDL) by extension officers following

persistent degeneration of the cattle despite completing the prescribed treatment regimen. After receiving the case, details captured were entered into a case file at CDL. Subsequently, a resident clinician was dispatched to visit the farm, collect history, thoroughly examine the sick animal and its environment, and to collect blood and fecal samples from the animal when necessary. The clinical history collected included age, breed, sex, management system, date for onset of clinical symptoms and the record of previous treatments given. Information regarding the clinical examination included weight, body condition score and measuring the rectal temperature.

## 2.2 Surgical Procedure

Following the diagnosis, discussions were held with the farmers to decide on the necessary actions which included either surgery or culling off the animal. Once consent was obtained to perform surgery, a stay suture rumenotomy was performed as described previously [14]. Briefly, the animal was restrained and the left para-lumbar fossa area was shaved and disinfected with cotton soaked in Iodine tincture. A 2% lidocaine hydrochloride local anaesthetic solution was infused at the site in an inverted-L pattern. A 15-20 cm incision was made at the center of the para-lumbar fossa, approximately 10cm on the posterior end, parallel to the contour of the last rib. The external oblique, internal oblique and the transversus abdominis muscles were incised bluntly to expose the peritoneum, which was opened initially by making a stab incision to permit pressure balance within the abdominal cavity. The wall of the rumen was thoroughly inspected for any adhesions by making a gentle sweep using the surgeon's hand covered with sterile arm length gloves. After examination, an incision was made into the rumen to expose the ingesta, followed by exploration of the ingesta for plastic bags and other indigestible materials. A magnet was used to make a gentle sweep to attract any metallic indigestible materials within the rumen and the reticulum.

## 2.3 Closure of the Incision and Post-operative Care

The incision was then closed as follows; the rumen was closed using two layers of inverting simple continuous suture patterns with chromic catgut suture material (chromisorb<sup>®</sup>, USP 2-0). The peritoneum and the transversus abdominis muscle were closed with catgut suture material

using a simple interrupted pattern. The external and internal oblique muscles were closed with chromic catgut using a simple continuous suture pattern. The subcutis was then closed with polyglactin 910 (Vicryl<sup>®</sup>, 1) using a simple continuous pattern and finally, the skin was apposed with nylon suture material (NYLON MONOFILAMNT<sup>®</sup>, USP 2) using a horizontal mattress suture pattern. Post-operative care included intramuscular injections of Pen-Strep<sup>®</sup> and multivitamin (Norbrook Laboratories, Newry, North Ireland) at the recommended dosage q.d. for 3 days. Whereas an Alamycin<sup>®</sup> wound spray was applied q.a.d. until the patient recovered. Patients whose health conditions were dire received 300 ml of propylene glycol per os, q.d. for 3 days.

## 2.4 Retrospective Review of Cases Reported to CDL in 2018 Following Suspicion of Hardware Disease

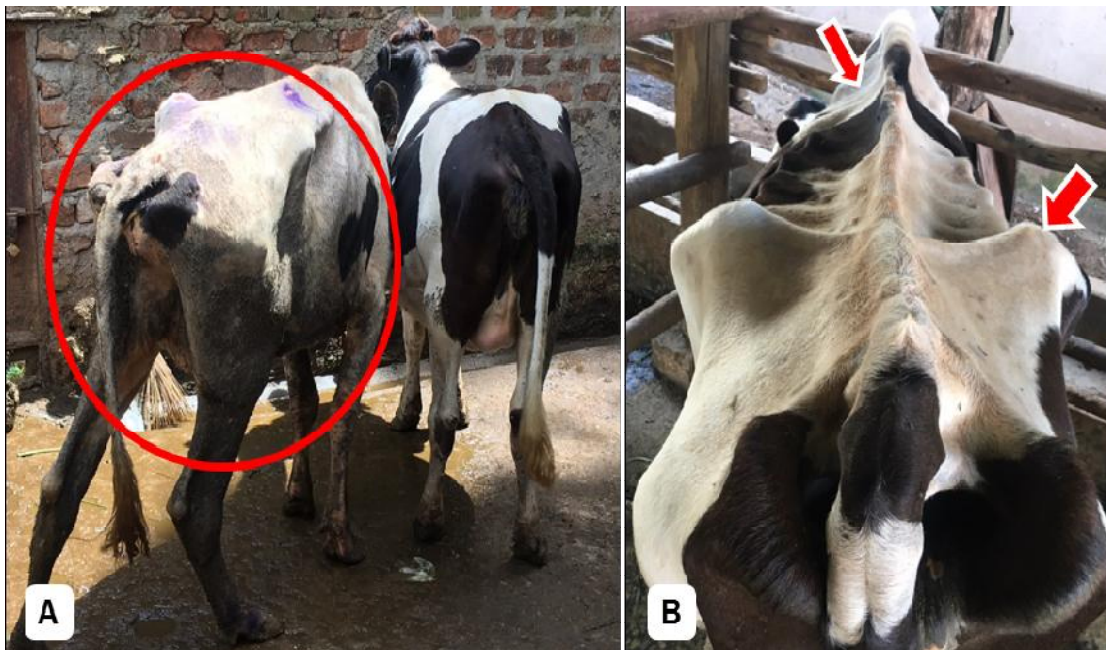
Prompted by the findings from the 3 cattle operated, a retrospective review of all the blood samples submitted to the hematology unit in 2018 was performed. Information was obtained from the forms where the submitter indicated hardware disease as the suspected disease. The information captured included the date, district, breed, age, sex, clinical signs and the diseases suspected. The data was packaged into excel and presented in tabular form.

## 3. RESULTS

### 3.1 Clinical Findings

Case 1 was for a tethered cow found in Wakiso district. Based on the history, the cow was reported to the extension officer with signs of emaciation, reduced appetite and teeth grinding (Table 1). She was dewormed and injected with antibiotics, anti-trypanosome, and anti-protozoa drugs. However the condition persisted prompting a referral.


Case 2 was for a 5 year old zero grazed cow from a herd of 5 animals in Kasangati, Wakiso district. From the information collected, she had suffered for at least 8 months before the surgery was performed (Fig. 1). Similarly to case 1, she was treated for helminthiasis, *trypanosomiasis* and *anaplasmosis*. Despite the treatment, her condition worsened prompting the farmer to involve another extension worker who also attempted more treatment regimen before referring the case to CDL for rumenotomy.



**Fig. 1. The emaciated animals following ingestion of indigestible materials. The red circle in Image A shows the affected animal in proximity to a healthy one. The red arrows in image B shows the protruding bone prominences of the animal with an indigestible material**

Case 3 was of a 2 year old bull found on a paddocked farm of 14 cattle, in Wakiso district. At the time of the visit the bull had a normal rectal temperature but was severely emaciated. Only two weeks ago, the animal had a fever and received treatment against *anaplasmosis* and *theileriosis*, after which his demeanor and appetite improved for only 2 days before reverting to solitude, lethargy and staggering gait. Congruent to hardware disease diagnosis,

the farmer reported having lost a heifer 4 months ago under similar circumstances. Upon slaughter, the heifer was found with plenty of plastic bags in the rumen. Affirmatively, the visiting veterinarian observed several plastic bags littered all over the pasture. When the veterinarian raised the concern, the farmer responded that “they (plastic bags) were blown by wind from the plastic bag recycling factory neighboring the farm”.



**Fig. 2. Indigestible materials that include plastic bags, rope, and wire retrieved from the rumen and reticulum of the affected cattle. The red arrow shows the metallic wire removed from the reticulum of the animal in case 2**

**Table 1. The descriptive data for the positive cases of foreign material handled by the ambulatory clinic at CDL**

<b>Case ID</b>	<b>Date</b>	<b>Location:</b>	<b>Management system</b>	<b>Characteristics: Breed, Age, Sex</b>	<b>History</b>	<b>Clinical parameters: Wt, BCS, Temp,</b>	<b>Indigestible materials</b>
Case 1: 18-2545	April/ 2018	Wakiso	Tethering	Holstein Friesian 4 years Female	Innapetence Weight loss Lethargy Non responsive to treatment	254 kg 1.5 39.6 <sup>0</sup> C	Plastic bags Nail
Case 2: 18-2145	May/ 2018	Wakiso	Zero grazing	Holstein Friesian 5 years Female	Innapetence Weight loss Persistent watery diarrhea Non responsive to treatment	239 kg 1.5 39.3 <sup>0</sup> C	Plastic bags Sisal rope Wire
Case 3: 18-2715	Nov/2018	Wakiso	Paddocking	Holstein Friesian 2 years Male	Weight loss Intermittent fever Mild response to treatment Mucous on the feces Lack of appetite	172 kg N/A 39.5 <sup>0</sup> C	Plastic bags Wire

*Wt: weight in kilo grams, BCS: body condition score on a scale of 5, Temp: temperature in degrees centigrade*

### 3.2 Indigestible Contents Retrieved after Surgery

Plastic bags and a nail were removed from the rumen and reticulum of the animal in case 1 (Fig. 2). In case 2, plastic bags, a sisal rope and a wire were retrieved from the rumen (Fig. 2). Notably, one end of the rope was entwined into a ball like structure which was lodged in the reticulum. In case 3, plastic bags were found in the rumen while a 5 cm long nail was retrieved from the reticulum. Among the animals operated, case 1 recovered and regained productivity while the other two animals (Cases 2 and 3) died 7-10 days after surgery.

### 3.3 Other Cases Reported to CDL Following Suspicion of Hardware Disease

In total, 23 suspected cases were reported to the Central Diagnostic Laboratory for diagnosis of hardware disease in the year 2018 (Table 2). Majority, 82% (19/23) were submitted from Kampala and neighboring districts; Wakiso and Mukono while the other 4 cases came from other districts such as Luweero, Nakaseke and Sembabule. Regarding the breed, Holstein Friesian was the most dominant contributing 87% (20/23) to the total sample size while a Jersey and two Ankole blood samples were submitted. All the farmers included emaciation as the most common clinical feature attributed with hardware disease followed by starry hair coat, lethargy and diarrhea. The rarely reported clinical signs in the current report included submandibular edema, arched back and recumbence. Among the 23 cases, 8 cases recorded hardware disease solely as the suspected disease while the rest recorded it with other diseases such as *helminthiasis*, fascioliasis, hemoparasites, para-tuberculosis (Johnes' disease) and coccidiois.

## 4. DISCUSSION

The availability of market for milk coupled with logistical support from government and other Non-governmental organizations have fostered the peri-urban dairy farming in Uganda [11,15]. However, the peri-urban farmers have to cope with limited space and feed scarcity. Adaptively, the farmers utilize crop residues (Fig. 3) from sources that include homes, markets and food processing plants to feed the animals [10]. Unfortunately, the chain of processing that such

feed goes through inescapably subjects it to contamination with plastic bags, metals and chemicals.

In Uganda, plastic bag pollution is rampant. In recent years, the use of plastic bags has been condemned and almost banned due to the environmental pollution, soil degradation and public health concerns posed [16]. None the less, the attempts to ban plastic bags have failed due to political influence and business interests [17]. Currently, over 40 plants continue to import and distribute over 2,000 tons of plastic bags into Uganda per year [18]. Sadly, this occurs without a nationwide plastic bag recollection strategy leading to unchecked pollution of the water, soil and pastures [19,20]. Withstanding, the implications of plastic bag waste on livestock production remains concealed. To date, no record documents plastic bag effects on livestock production in Uganda and yet subjective evidence suggests it is a growing concern. This article provides baseline data regarding the effect of plastic bags on cattle among dairy farms in the peri-urban Kampala.

In this report, referral cases reported to the ambulatory unit of the Central Diagnostic Laboratory (CDL) were diagnosed and surgically treated. Indigestible materials such as plastic bags, rope, wire and nails (Fig. 1) were recovered from the rumen and reticulum of the animals involved in the current study. The indigestible materials found were familiar with those reported in previous studies conducted in Ethiopia [21] and Tanzania [2]. Furthermore, those studies reported a prevalence of indigestible materials in cattle to be 24 and 13 % in Tanzania and Ethiopia, respectively. Since the livestock production systems may not differ much from those in neighboring Ethiopia and Tanzania, we could speculate that the prevalence of indigestible materials among cattle reared in Uganda is equally high. Concordantly, a retrospective search through the archives for samples recorded by the hematology unit by CDL in 2018 showed that 23 other cases were submitted for blood chemistry analysis over suspicions of indigestible materials (Table 2). Certainly the burden of indigestible materials in Uganda is worrying and compels a further study to determine its prevalence.

Of the three animals operated, two were female Holstein Friesians in productive stage while the other was a young male yet to attain its reproductive purpose. Regrettably, two of the

animals died following surgery. The death could be blamed on the fact that at the time of the surgical intervention, they were in poor body condition and emaciated due to indigestible material induced nutrient deprivation [22]. A

previous study [1] has shown that non-metallic indigestible materials have the ability to cause ruminal stasis and impaction of the reticulum-abomasum orifice thence impairing digestion.



**Fig. 3.** Crop residues such as banana and potato peels used to feed cattle. The red arrows in Image C show the plastic bags found in the feed trough at one of the farms visited



**Fig. 4.** A cow scavenging for feed from a garbage dump near a grazing area in Kampala

**Table 2. The description of cases submitted to the Hematology unit at CDL in the year 2018, following suspicion of hardware disease**

S/N	Date	District	Breed	Age	Sex	Clinical signs reported	Diseases suspected
1	Jan	Kampala	HF	Adult	F	Emaciation, severe diarrhea	HD
2	April	Wakiso	HF	Adult	F	Emaciation, anorexia, lacrimation, rectal temp: 38.2 <sup>0</sup> C	HD
3	April	Kampala	HF	Adult	F	Emaciation, lethargy, rectal temp: 40.1 <sup>0</sup> C	Hemoparasites, HD
4	April	Wakiso	HF	Adult	F	Emaciation, starry hair coat	Hemoparasites, HD
5	May	Wakiso	HF	NA	M	Emaciation	HD
6	May	Nakaseke	Ankole	Heifer	F	Emaciation, anorexia, rectal temp: 39.0 <sup>0</sup> C	HD, Hemoparasites
7	May	Wakiso	HF	Adult	F	Emaciation, starry hair coat, agalactia	HD, Helminthiasis
8	May	Luweero	HF	Adult	F	Emaciation, starry hair coat	HD
9	June	Sembabule	Ankole	Adult	F	Persistent diarrhea	HD
10	June	Wakiso	HF	NA	F	Emaciation, starry hair coat, hatched back, diarrhea	Helminthiasis, HD
11	July	Nakaseke	HF	Adult	F	Progressive emaciation	HD, Hemoparasites
12	July	Kampala	HF	Adult	F	Emaciation, innapetence, agalactia, rectal temp: 39.5 <sup>0</sup> C	Hemoparasites, HD
13	July	Mukono	Jersey	Adult	F	Emaciation, starry hair coat, chronic diarrhea, rectal temp: 41.8 <sup>0</sup> C	HD, Paratuberculosis
14	July	Wakiso	HF	Yearling	M	Emaciation, diarrhea, recumbence	Coccidiosis, HD
15	July	Wakiso	HF	Adult	F	Emaciation, lethargy, agalactia	Hemoparasites, HD
16	Aug	Wakiso	HF	Heifer	M	Emaciation, lethargy, rectal temp: 39.5	HD
17	Aug	Kampala	HF	Adult	F	Emaciation, recumbence, innapetence, submandibular edema	HD, Hemoparasites
18	Oct	Wakiso	HF	NA	F	Emaciation, reluctant to move, starry hair coat	Fascioliasis, HD
19	Oct	Wakiso	HF	Adult	F	Emaciation, selective feeding, mild diarrhea, rectal temp: 38.9	HD
20	Oct	Mukono	HF	Heifer	F	Emaciation, lethargy, starry hair coat	Fascioliasis, HD
21	Nov	Wakiso	HF	Adult	F	Emaciation, submandibular edema	Helminthiasis, HD
22	Nov	Wakiso	HF	Adult	F	Severe emaciation	Helminthiasis, HD
23	Nov	Mukono	HF	Adult	F	Emaciation, selective feeding, labored breathing	HD

HD: Hardware disease, HF: Holstein Friesian, temp: Temperature in degrees centigrade



Excruciatingly, the diagnosis of hardware disease is complex and requires sophisticated equipment such as an ultra sound machine, X-ray machine and metal detectors which may not be readily available in developing countries [9]. As such, by the time diagnosis is confirmed, the animal has suffered severely and it is at the blink of death. For instance, the three cases in this report were first misdiagnosed and treated for other diseases and conditions that include *helminthiasis*, *trypanosomiasis* and *anaplasmosis* before suspecting an indigestible material.

Taken together, plastic bags and other indigestible materials impart heavy production losses and ill-health implications on the dairy sector [23]. In the long run, this contradicts the purpose of the peri-urban farming to provide milk for nourishment and also to generate income. Regrettably, the plastic bags pollution in Uganda is startling due to poor solid waste disposal manners among the city dwellers, lack of government aided rigorous systematic processes to recollect the used plastic bags or to ban plastic bag use [24].

The findings of this study suggest a need to sensitize the farmers on proper sorting of the feeds to avoid exposing their cattle to indigestible materials. Even though zero grazed animals are more prone to suffer from the consumption of plastic bags, it is common to find free ranging cattle scavenging from open rubbish dumping sites in the peri-urban areas (Fig. 4). The driver for such a behavior could be the nutritional deficiency of the feeds provided, taste of the contents in the plastic bags or just curiosity [5]. However, the outcome for such cattle may be death. Therefore, the municipal councils need to take the initiative to fence off the dumping sites.

## 5. CONCLUSION

In summary, indigestible materials such as plastic bags pose a serious threat to the realization of the anticipated profit margin for the peri-urban dairy farmers. The farmers incur losses through low milk production, cost of surgery and treatment, and death of their cattle. Therefore, doing nothing to reduce the exposure of dairy cattle to indigestible material condemns the peri-urban dairy farmers into poverty. As a proposed countermeasure, awareness of farmers coupled with increased vigilance of the population towards plastic bag use is required to reduce hardware disease and its effects on the

eco, human and animal health in the urban and peri-urban centers.

## CONSENT

Verbal consent was taken from the cattle owners.

## ETHICAL APPROVAL

As per international standard or university standard written ethical permission has been collected and preserved by the author(s).

## ACKNOWLEDGEMENTS

The authors thank the extension officers for referring the cases to the ambulatory clinic at the Central Diagnostic Laboratory.

## COMPETING INTERESTS

Authors have declared that no competing interests exist.

## REFERENCES

1. Reddy R, Latha A, Reddy S. Review on metallic and non-metallic foreign bodies a threat to livestock and environment. *Int J Food*. 2014;4:6–14.
2. Bwatota SF, Makungu M, Nonga HE. Occurrences of indigestible foreign bodies in cattle slaughtered at Morogoro municipal slaughterhouse, Tanzania. *J Vet Med*. 2018;1–6. DOI:10.1155/2018/4818203.
3. Braun U, Warislohner S, Torgerson P, Nuss K, Gerspach C. Clinical and laboratory findings in 503 cattle with traumatic reticuloperitonitis. *BMC Vet Res* 2018;14:66. DOI:10.1186/s12917-018-1394-3.
4. El-Ashker M, Salama M, El-Boshy M. Traumatic reticuloperitonitis in Water Buffalo (*Bubalus bubalis*): Clinical findings and the associated inflammatory response. *J Vet Med* 2013;2013:808656. DOI:10.1155/2013/808656.
5. Rehage J, Kaske M, Stockhofe-Zurwieden N, Yalcin E. Evaluation of the pathogenesis of vagus indigestion in cows with traumatic reticuloperitonitis. *J Am Vet Med Assoc*. 1995;207:1607–11.
6. Braun U, Warislohner S, Gerspach C, Ohlerth S, Nuss K. Treatment of 503 cattle with traumatic reticuloperitonitis. *Acta Vet Scand*. 2018;60:55. DOI:10.1186/s13028-018-0410-8.
7. Braun U, Jacquat D. Ultrasonography of

- the reticulum in 30 healthy Saanen goats. *Acta Vet Scand.* 2011;53:19. DOI:10.1186/1751-0147-53-19.
8. Braun U, Götz M. Ultrasonography of the reticulum in cows. *Am J Vet Res.* 1994;55:325–32.
  9. Habasha FG, Yassein SN. Advance techniques in traumatic reticuloperitonitis diagnosis : Review. *AL-Qadisiya J Vet Med Sci.* 2014;13:50–7.
  10. Mary T, Ewa W, Elly NS, Denis M. Feed resource utilization and dairy cattle productivity in the agro-pastoral system of South Western Uganda. *African J Agric Res.* 2016;11:2957–67. DOI:10.5897/AJAR2016.10785.
  11. Benon KM, Owiny DO, Båge R, Nassuna-Musoke MG, Humblot P, Magnusson U. Managerial practices and factors influencing reproductive performance of dairy cows in urban/peri-urban areas of Kampala and Gulu, Uganda. *Acta Vet Scand.* 2015;57:35. DOI:10.1186/s13028-015-0122-2.
  12. Tayebwa D, Bigirwa G, Byaruhanga J, Kasozi K. Prevalence of endometritis and its associated risk factors in dairy cattle of Central Uganda. *Am J Exp Agric.* 2015;7:155–62. DOI:10.9734/AJEA/2015/15816.
  13. Byaruhanga J, Tayebwa DS, Eneku W, Afayoa M, Mutebi F, Ndyanabo S, et al. Retrospective study on cattle and poultry diseases in Uganda. *Int J Vet Sci Med* 2017;5:168–74. DOI:10.1016/j.ijvsm.2017.07.001.
  14. Zangaglia R, Martignoni E, Glorioso M, Ossola M, Riboldazzi G, Calandrella D, et al. Macrogol for the treatment of constipation in Parkinson’s disease. A randomized placebo-controlled study. *Mov Disord* 2007;22:1239–44. DOI:10.1002/mds.21243.
  15. Sudhir K, Kalule C. Milk production and marketing in Uganda: Current situation , requirements and way forward. 2014;1:1–8.
  16. Rayne S. The need for reducing plastic shopping bag use and disposal in Africa. *African J Environ Sci Technol.* 2008;3:7–9.
  17. Daily Monitor News. The politics of kaveera and government failure to ban it - Daily Monitor 2011:17/September. Available:https://www.monitor.co.ug/SpecialReports/688342-1237618-a58xdc/index.html (accessed December 14, 2018).
  18. Daily Monitor News. Museveni bans polythene bags - Daily Monitor 2018:06/June. Available:https://www.monitor.co.ug/News/National/Museveni-polythene-bags--Environment-Water-Nema/688334-4597772-i9d4n5/index.html (accessed December 14, 2018).
  19. Mogomotsi PK, Mogomotsi GE, Phonchi ND. Plastic bag usage in a taxed environment: Investigation on the deterrent nature of plastic levy in Maun, Botswana. *Waste Manag Res.* 2018:0734242X1880149. DOI:10.1177/0734242X18801495.
  20. Hammer J, Kraak MHS, Parsons JR. Plastics in the marine environment: The dark side of a modern gift. *Rev. Environ. Contam. Toxicol.* 2012;220:1–44. DOI:10.1007/978-1-4614-3414-6\_1.
  21. Chanie DT and M. Study on rumen and reticulum foreign bodies in cattle slaughtered at Jimma municipal abattoir, South West Ethiopia. *Am J Sci Res.* 2012;7:160–7. DOI:10.5829/idosi.ajejr.2012.7.4.65140.
  22. Nongcula VV, Zhou L, Nhundu K, Jaja IF. Association between the prevalence of indigestible foreign objects in the gastrointestinal tract of slaughtered cattle and body condition score. *Anim an Open Access J from MDPI.* 2017;7. DOI:10.3390/ani7110080.
  23. Akinrinmade. JF, Akinrinde AS. Bulletin of animal health and production in Africa. vol. 61. Inter-African Bureau for Animal Resources; 2013.
  24. Komakech AJ, Banadda NE, Kinobe JR, Kasisira L, Sundberg C, Gebresenbet G, et al. Characterization of municipal waste in Kampala, Uganda. *J Air Waste Manage Assoc.* 2014;64:340–8. DOI:10.1080/10962247.2013.861373.

© 2019 Tayebwa et al.; This is an Open Access article distributed under the terms of the Creative Commons Attribution License (<http://creativecommons.org/licenses/by/4.0>), which permits unrestricted use, distribution, and reproduction in any medium, provided the original work is properly cited.

*Peer-review history:*  
 The peer review history for this paper can be accessed here:  
<http://www.sdiarticle3.com/review-history/46844>