

PFNA2 versus 95 Degree Condylar Blade Plate in the Management of Unstable Trochanteric Fractures

Piyush Gadegone, Wasudeo Gadegone*, Vijayanand Lokhande, Virender Kadian

Department of Orthopaedic, Trauma and Orthopaedic Hospital, Chandrapur, India

Email: piyush.gadegone@gmail.com, *gadegone123@yahoo.co.in, *gadegone123@g.mail.com, Vijayanandlokhande1702@gmail.com, kadian_virender@yahoo.com

How to cite this paper: Gadegone, P., Gadegone, W., Lokhande, V. and Kadian, V. (2024) PFNA2 versus 95 Degree Condylar Blade Plate in the Management of Unstable Trochanteric Fractures. *Open Journal of Orthopedics*, 14, 93-104.
<https://doi.org/10.4236/ojo.2024.142010>

Received: November 28, 2023

Accepted: February 5, 2024

Published: February 8, 2024

Copyright © 2024 by author(s) and Scientific Research Publishing Inc. This work is licensed under the Creative Commons Attribution International License (CC BY 4.0).

<http://creativecommons.org/licenses/by/4.0/>



Open Access

Abstract

Purpose: The proximal femoral nail anti-rotation (PFNA) is known to have advantages in enhancing the anchorage ability of internal fixation in elderly unstable osteoporotic intertrochanteric fracture patients. However whether it is superior to condylar blade fixation is not clear. This study aimed to determine which treatment has better clinical outcomes in older patients. **Materials and Methods:** A total of 86 patients over the age of 60 with unstable trochanteric fractures within the past 3 weeks, were included in this prospective study conducted from June 1, 2018, to May 31, 2021. All the intertrochanteric fractures were classified according to AO/OTA classification. Among them, 44 cases were treated with the Proximal Femoral Nail (PFNA2) with or without an augmentation screw, and 42 cases were treated with the Condylar Blade Plate. In addition, the operative time, intraoperative blood loss, intraoperative and postoperative blood transfusion, postoperative weight-bearing time, hospitalization time, Harris score of hip function, Kyle's criteria and postoperative complications were compared between the two groups. **Results:** The mean duration of surgery for the PFN group was 66.8 minutes (on average), whereas for the condylar blade plate group, it was 99.30 minutes (on average). The PFNA2 group experienced less blood loss (average of 80 mL) compared to the condylar blade plate group (average of 120 mL). Union and partial weight-bearing occurred earlier in the PFNA2 group (14.1 weeks and 10.6 weeks, respectively) compared to the Condylar blade plate group (18.7 weeks and 15.8 weeks). In two patients from the PFNA2 group, screw backing out and varus collapse complications were encountered; however, these patients remained asymptomatic and did not require revision surgery. In two other patients, screw cut out and breakage of the nail at the helical screw hole leading

to non-union of the proximal femur were observed during the nine-month follow-up, necessitating revision surgery with prosthetic replacement. Among the condylar blade plate group, three patients experienced complications, including blade breakage at the blade and plate junction. In two cases, the fracture united in varus, and in one case, the blade cut through, resulting in non-union of the femoral head, which required revision surgery. According to the Harris hip score and Kyle's criteria, a good-excellent outcome was observed in 92.85% of cases in the PFNA2 group and 90.90% of cases in the condylar blade plate group. **Conclusion:** Both the Proximal Femoral Nail A2 and Condylar blade plate are effective implants for the treatment of unstable trochanteric fractures. The intramedullary implant promotes biological healing and allows for early ambulation with minimal complications. Similarly satisfactory restoration of anatomy and favorable radiological and functional results can be achieved with the biological fixation provided by the 95-degree condylar blade plate. However, the use of PFNA2 internal fixation technique has the advantage of less trauma in elderly patients than the 95-degree condylar blade plate.

Keywords

Proximal Femoral Nail Anti-Rotation, Condylar Blade Plate, Internal Fixation, Unstable Intertrochanteric Fracture, Osteoporotic

1. Introduction

Approximately 35% - 40% of fractures classified as unstable (AO/ASIF classification: 31-A2/31-A3) are associated with high morbidity and mortality rates [1]. Orthopedic surgeons face challenges when dealing with unstable intertrochanteric fractures (AO 31A2, AO 31A3), as the functional outcome tends to be disappointing despite high union rates [2] [3]. The presence of an intact lateral wall is crucial for stabilizing these fractures, as it provides support for the proximal fragment and prevents excessive collapse and varus malpositioning [4]. The fixation of unstable intertrochanteric fractures has been a subject of ongoing debate. There are conflicting reports regarding the use of intramedullary or extramedullary implants for the treatment of these fractures. The commonly used fixation methods include the sliding hip screw (SHS) and proximal femoral nail for intramedullary fixation. However, some authors suggest that SHS fixation is more suitable for stable fractures, while unstable trochanteric fractures fixation with an intramedullary device [5] [6].

The Proximal Femoral Nail (PFNA2) is a biomechanically stable intramedullary device used for fixing unstable osteoporotic trochanteric fractures. It offers advantages such as a short lever arm, an implant positioned close to the weight-bearing axis, bending and torsional stability, and reduced tensile strain on the implant [7]. It is the most favored implant in osteoporotic unstable trochanteric

fractures and it is a bone preserving implant as it compacts the bone around the blade. Another extramedullary bone-preserving implant is known as condylar blade plate which is mainly used in revision surgeries. It is not commonly employed for fresh unstable intertrochanteric fractures however it can also provide stable fixation in fresh trochanteric fractures. The anatomically pre-contoured 95-degree Condylar blade plate fits the proximal femur and offers angular stability through the placement of the blade and supra calcar screw, and plate on the shaft which shields the lateral trochanteric wall from stress [8].

This study aims to compare the outcomes of PFN A2 and Condylar blade plates in the management of unstable trochanteric fractures.

2. Materials and Methods

In this study, we included 44 cases of unstable trochanteric fractures treated with [proximal diameter of 16.5 mm and length of short PFN 18 cm and the standard 24 cm length] Proximal Femoral Nail (PFNA 2) with or without augmentation screw and 42 cases treated with the Condylar blade plate from June 1, 2018, to May 31, 2021. Patients over 60 years old who provided informed consent were eligible for the study. Institutional Ethics Committee approval was obtained, Exclusion criteria included patients with open fractures, fractures older than three weeks, pathological fractures, contraindications for surgery and patients who died during nine months follow-up and lost to follow-up cases were excluded.

Surgical Technique for Proximal Femoral Nail A2:

After anesthesia, the patient was positioned supine on a fracture table. Closed reduction was attempted using direct traction, abduction, and external rotation, as well as an intrafocal joystick with a 3.0 mm Kirschner wire inserted perpendicularly into the front part of the femoral neck. In reverse oblique fractures extending into the shaft, a cerclage wiring technique was used if necessary. An open reduction was performed if the closed method failed. Percutaneous anteromedial 3 mm two pins are passed to stabilize the fracture. Adduction of the limb is achieved to locate the proper entry portal. A skin incision of 3 - 5 cm was made 5 cm proximal to the greater trochanter's tip. The entry point was determined on the medial side of the greater trochanter in the anteroposterior view and between the anterior one-third and posterior two-thirds in the lateral view. A guidewire was inserted, followed by adequate reaming to prepare for nail insertion. Using a jig, the nail was manually inserted into the femoral opening. 2.5 MM guide wire was passed from the lateral surface of the femur through the neck to the subchondral position of the head in the center or slightly inferior in AP and center in lateral view, followed by the placement of a helical blade of appropriate length. Predetermined compression of 5 mm - 8 mm is achieved. From the lateral side of trochanter guide wire is passed lateral to medial and the augmentation screw with washer is inserted anterior to the helical blade to buttress the lateral wall in fifteen cases. Additional cerclage wire was used in four cases in fracture extending to the shaft. Proper rotation of the distal fragment was con-

firmed, followed by distal locking with a jig. The device was dynamically locked distally to enable compression across the fracture site. The surgery was performed under an image intensifier. The wound was closed layer by layer after achieving hemostasis (**Figure 1**).

Surgical Technique for Condylar Blade Plate:

After administering anesthesia, the patient was placed on a fracture table, and closed reduction was performed using the same reduction methods as described for the PFN, with the operated limb in abduction. If closed reduction is unsuccessful open reduction is done. A straight incision from the greater trochanter allowed for a lateral approach to the proximal femur without compromising vascularity. After ensuring a perfect anatomic reduction, clamping of the fracture was done to stabilize the anteromedial and posterolateral fragments. A 95-degree angle guide was placed laterally at the flare of the trochanter, and the guide wire was inserted at an average of 10 mm below the superior part of the neck, ensuring distal placement at the inferior quadrant of the femoral head in the anteroposterior and lateral views. The guide wires were position confirmed by fluoroscopy. The lateral cortex was drilled before inserting the condylar blade plate chisel to prevent lateral wall fracture. The plate was held and aligned with the shaft, and a condylar blade of appropriate length was inserted. A conventional 6.5 mm screw was used in the first hole of the plate, just touching the calcar below the tip of the blade. The plate was secured with bicortical 4.5 mm cortical screws. To distribute stress on the plate and reduce strain at the fracture, at least four holes in the plate were used. In the majority 65 blade length was used and in fragmented trochanter additional screw with a washer is passed above the condylar blade to stabilize the lateral wall. The final position was checked under a C-arm, a drain was placed, and the wound was closed in layers with an antiseptic dressing applied (**Figure 2**).

Assessment of Blood Loss:

Intraoperative blood loss was assessed using the mopping method, exclusively with a dry mop. The weight gained in the mop was used to calculate the amount of blood loss. Any complications occurring during the operation were recorded.

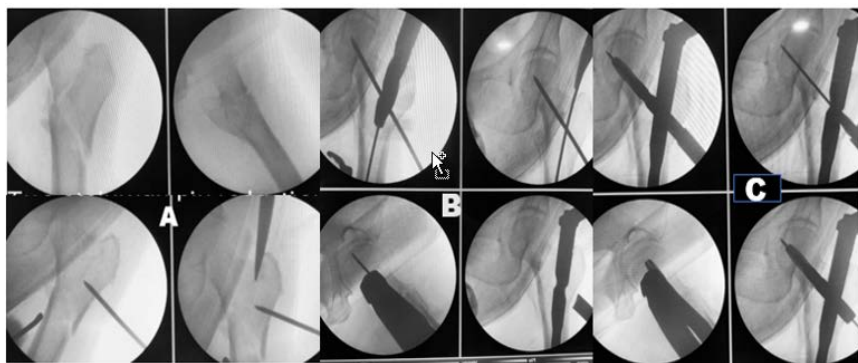


Figure 1. PFN Procedure. (A) Reduction and entry point (B) Guide wire and Nail insertion (C) Final placement of PFN.

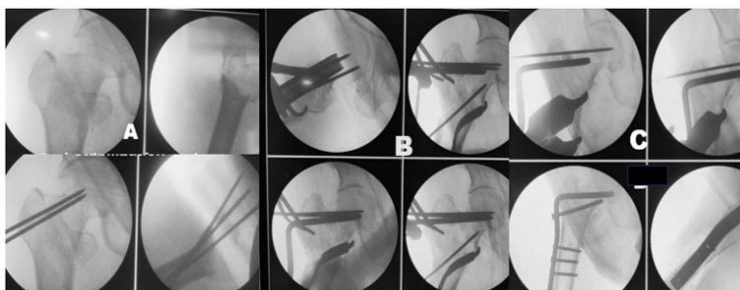


Figure 2. (A) Reduction and stabilization with K wire; (B) 95 Degree Chisel guide; (C) Blade and plate insertion.

Postoperative Regimen:

Postoperative X-rays were conducted, and sutures were removed on the 10th to 12th day after surgery. Patients were allowed non-weight bearing walker-assisted ambulation based on their pain tolerance. Full non-assisted weight-bearing was permitted once clinical and radiological signs of fracture union were evident. Follow-up appointments were scheduled at 4, 6, 8, 12, 16 weeks, and 6 months in the Orthopaedics OPD. At each visit, patients were clinically evaluated, and X-rays of the affected hip and femur were taken to assess fracture union, functional outcome, and any complications. Clinical findings included supratrochanteric shortening, broadening of trochanteric prominence, external rotation attitude of the limb, and ipsilateral abductor insufficiency and varus angle. Functional outcomes were assessed at each follow-up visit using the Harris Hip score and Kyle's criteria [9] [10].

3. Results

A total of 86 patients with unstable intertrochanteric fractures (AO/OTA type 31-A2.2 and 31-A2.3) who met the inclusion and exclusion criteria were included in the study. They were randomly divided into Group 1 (44 patients) treated with the PFNA2 and Group 2 (42 patients) treated with the Condylar blade plate alone. **Table 1** provides an overview of all demographic characteristics and intraoperative variables of the patients.

The mean age in group 1 was 59.03 ± 16.10 (range 51 to 85 years), with a male-predominance. Sixty-one patients sustained injuries due to slipping and falling on the ground, twenty patients sustained injuries due to road traffic accidents (RTA), and three patients sustained injuries due to falling from height. In group 1, 16 patients had 31A2 type and 28 patients had 31A3 type fracture patterns while in group twelve patients had 31A2 type and 30 patients had 31A3 type fracture patterns. In group 1, the average injury to surgery duration was 8.03 ± 1.5 days while it was 7.06 ± 1.74 days in group 2. The mean duration of surgery in group 1 was 66.82 ± 10.37 minutes, whereas it was 99.29 ± 10.87 minutes in group 2. The estimated mean blood loss in group 1 was 80.36 ± 12.89 ml, while in group 2, it was 103 ± 13.17 ml, but no significant difference was observed. Only patients who have less than 9 gm Hb received an intraoperative blood transfusion.

Table 1. Pre & intra-operative variables.

Variables	PFN A2 (n = 44)	Condylar blade plate (n = 42)
Mean age (years)	65.09 ± 6.82	62.86 ± 9.55
Sex	Male:28 Female:16	Male:24 Female:18
Mode of injury	RTA:12 self fall: 30 Falling from height 2	RTA:10 self fall: 31 Falling from height 1
AO fracture classification type AO31-	AO31-2.2: 6; AO31-2.3: 10; AO31-3.1: 6; AO31-3.2: 8; AO31-3.3: 14	AO31-2.2: 2; AO31-2.3: 10; AO31-3.1: 8; AO31-3.2: 5; AO31-3.3: 17
Time interval between trauma and surgery	7.95 ± 2.70 days	7.14 ± 1.82 days
Duration of surgery	66.82 ± 10.37 minutes	99.29 ± 10.87 minutes
Blood loss	80.36 ± 12.89 mL	103 ± 13.17 mL
Duration of hospital stay	15.32 ± 3.55 days	15.67 ± 2.75 days

All the postoperative characteristics of the patients are depicted in Table 2.

Patients with hemoglobin levels less than 9 g/dL during operation received blood transfusions according to the standard hospital protocol. Consequently, sixteen patients in group 1 and twenty-five patients in group 2 received blood transfusions. The average union time of the fracture in group 1 was 14.09 ± 2.31 weeks while it was 18.71 ± 3.45 weeks in group 2 ($p = 0.055$). At the 9-month follow-up, the average functional outcome was evaluated by Functional outcome in terms of Harris hip score (HHS) and Kyle's criteria in group 1 the score was 89.05 ± 6.18 whereas it was 90.64 ± 3.23 in group 2, and the difference was found to be statistically not significant ($p = 0.011$). Group 1 had 40 patients (90.90%) with excellent to good results, while group 2 had 39 patients (92.85 %) with excellent to good results. Four patients in group 1 and three patients in group 2 had poor outcomes at the 9-month follow-up (**Figure 3** and **Figure 4**).

Superficial infections were seen in one patient in group one and three patients in group two. It was managed with dressings and oral antibiotics as per culture-sensitivity reports. Two patients from group 1 encountered the complication of screw backing out and varus collapse but the patient had no clinical symptoms and did not need revision surgery. In two patients we noticed a screw cut out and nonunion of the proximal femur during the nine-month follow-up which required revision surgery of prosthetic replacement, Three patients in group 2 experienced complications, breakage of the blade at the blade and plate junction but fracture united in varus in two cases and blade cut through and nonunion from the femoral head requiring a revision hence these cases are included in bad results. The complication rates were found to be equal in both groups except for slightly greater exposure in the condylar blade plate group.

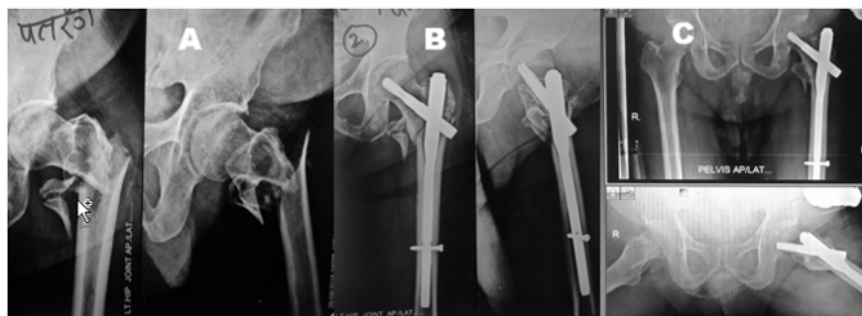


Figure 3. (A) Reverse oblique fracture A3 Fracture; (B) Post-op x-ray; (C) One year follow up. Good union.

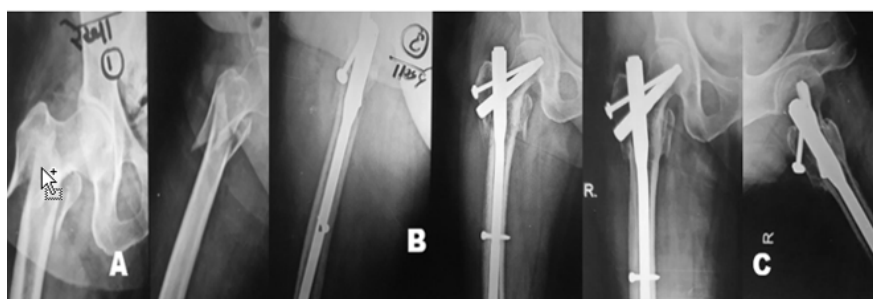


Figure 4. (A) Reverse oblique fracture A3 Fracture; (B) Post-op PFN with augmentation screw; (C) Nine months follow up. Good union.

Table 2. Union and functional outcome.

Variables	PFNA2 (n = 44)	Condylar blade plate (n = 42)
Mean time to union	14.09 ± 2.31 weeks	18.71 ± 3.45 weeks
Period of early ambulation	Walker assisted ambulation with tip toe touch down on operated limb: 9.14 ± 3.68 days	Walker assisted ambulation with tip toe touch down on operated limb: 42.24 ± 10.06 days
	Walker assistance on both sides: 4.91 ± 1.02 weeks	Walker assistance on both sides: 10.81 ± 1.12 weeks
	Full weight bearing with one stick if required: 14.09 ± 2.31 weeks	Full weight bearing with one stick if required: 18.76 ± 3.52 weeks
Functional outcome in terms of Harris hip score (HHS) and Kyle's criteria	At 6 months: 85.10 ± 6.20 At 9 months: 89.05 ± 6.18	At 6 months: 86.68 ± 5.35 At 9 months: 90.64 ± 3.23
	Excellent to good results 40 patients (90.90%)	39 patients (92.85%)

4. Discussion

Various surgical techniques have been described for the fixation of unstable trochanteric fractures, including intramedullary and extramedullary devices.

However, the use of intramedullary fixation with the proximal femoral nail (PFN) and PFNA2 in osteoporotic unstable trochanteric fractures is becoming more popular compared to the sliding hip screw due to its advantages, such as reduced limb shortening, decreased collapse at the fracture site, and lower implant failure rates [11]. Although functional outcomes achieved with both implants are similar, PFNA2 is more advantageous than PFN with two screws passed through a deficient lateral wall. The helical blade has the ability to create visible compression and impaction at the fracture site. It has a clear End cap with a locking helical blade within the nail preventing its backout and reducing complications related to it. PFNA2 is better than PFN in lateral wall deficient intertrochanteric femur fracture [12]. The use of an augmentation screw with a washer helps in the stabilization of the lateral wall and also enhances the stability of fixation which is required in fifteen patients. Other bone preserving implants, the condylar blade plate is primarily utilized for nonunion and revision surgeries of proximal femoral fractures and is rarely used for fixing unstable fractures. In elderly patients with unstable intertrochanteric fragility fractures, the fixed angled condylar blade plate seems to be a better choice than dynamic hip screws for preventing fixation failures [13]. The objective of our study was to compare the functional and radiological outcomes of patients with unstable intertrochanteric fractures treated with two different fixation devices: the proximal femoral nail A2 and the condylar blade plate.

We conducted a study on 86 patients (44 treated with PFNA2 and 42 treated with the condylar blade plate) with unstable trochanteric fractures in the Department of Orthopaedics and Trauma from June 2018 to May 2021. Our aim was to examine, evaluate, document, and quantify the results in terms of peri-operative measures, early ambulation, fracture union, functional outcome, and complications. The use of PFN proved to be beneficial in the treatment of unstable trochanteric femoral fractures, as it was a relatively straightforward procedure and provided biomechanical stability, allowing for early weight bearing [6] [7]. A previous study on 130 intertrochanteric fractures with lateral femoral wall fractures treated with intramedullary fixation showed that lateral trochanteric wall fractures might affect the stability of intertrochanteric fractures. Therefore, some authors have recommended the use of intramedullary fixation, and in cases where the lateral wall is broken, augmenting the PFN with an additional screw, cerclage wire or trochanteric buttress plate can lead to faster union, early weight bearing, better reduction, and improved hip function [14] [15] [16]. However, this approach may increase surgical time, blood loss, and radiation exposure.

In our study, we used PPFNA2 with an augmentation screw to buttress the lateral wall and to improve the stability of the construct. The mean surgery duration for PFN A2 was shorter than that for the condylar blade plate. Additionally, blood loss was lower with PFNA2 compared to the condylar blade plate. Fracture union occurred earlier in the PFNA2 group than in the condylar blade plate group. However, there was no significant difference between the two groups in

terms of partial weight-bearing and full weight-bearing. Nonunion occurred in two fractures in both groups.

At 9 months postoperatively, the average Harris hip score was slightly higher for the PFNA2 group, although the difference was not statistically significant. The majority of patients in both groups achieved excellent to good results, with a small percentage experiencing unsatisfactory outcomes after nine months of follow-up. Postoperative superficial surgical site infections were more common in the condylar blade plate group, but all cases responded well to conservative treatment with antibiotics. The rates of complications between PFNA2 and the condylar blade plate did not differ significantly. However, there was a significant difference in fracture union time between the two groups.

In one study nine cases in the PFNA group required additional procedures, such as cerclage wiring for lateral wall reconstruction apart from the use of an additional screw with a washer to improve fixation stability. Another study showed that in unstable intertrochanteric fractures, the use of PFNA2 with an extra screw or cerclage wire improves construct efficacy and stability, facilitating union and shortening the time to union [17] [18] [19]. In our study we required additional fixation by augmentation screw with a washer and four cases of additional cerclage wire. However, these additional procedures require further incisions and fracture exposure. Recent literature supports the use of intramedullary implants over extramedullary implants for reverse oblique fractures, as fixation with a dynamic hip screw alone yields poor results [20] [21]. In a study by Sharan Mallya *et al.* the overall complications, in the set-up of osteoporosis, seen with both the implants PFN and PFNA2 were similar. PFNA2 group showed better results in terms of perioperative morbidity [22].

In our study, we observed less postoperative limb shortening, and better anatomical restoration with condylar blade plate as it is an open method where visualization of fixation is possible as compared to PFNA2 which is mostly a closed procedure. The condylar blade plate functions as a load-sharing and bone-preserving implant. It is pre-stressed and placed on the tension side of the fracture, acting as a tension device. It facilitates anatomical and biological reduction, and the lateral plate provides stress shielding for the lateral fragment, similar to the DHS with TSP/plate (PCCP) designed by Gotfried [23]. It prevents rotation of the proximal femoral head fragment and allows for fracture compression, eliminating the need for additional procedures to address the lateral wall. A recent study has shown that 95-degree condylar blade plate fixation is a reliable and effective treatment for trochanteric fractures [24]. The surgical technique and final implant position also influence the results in unstable trochanteric fractures. Ideal implant positioning involves placing the blade tip in the lower half of the femoral head, passing the blade below the superior cortex of the neck. The 95-degree condylar blade plate produces comparable results to the proximal femoral nail. In literature there is no comparative study available between PFNA2 and condylar blade plate hence we tried to compare two systems of fixation for unstable trochanteric fracture and reverse intertrochanteric fractures with great-

er trochanteric comminution. Though PFN and PFNA2 are implants of choice, we suggest that Condylar blade plate is a good choice with less expensive and requires minimal C Arm exposure in such fractures.

Limitations of our study include a small sample size and short-term follow-up. Further biomechanical and clinical studies are needed to evaluate the efficacy of PFNA2 and the condylar blade plate.

5. Conclusion

PFNA2 offers intraoperative advantages such as a shorter incision, shorter surgery duration, and less blood loss compared to the condylar blade plate. The condylar blade plate may result in slightly more blood loss and longer surgery duration due to open reduction, it allows for open reduction and repositioning of the lateral wall with its buttressing effect. The condylar blade plate is also an optimal implant for the treatment of unstable trochanteric fractures, especially those with a floating lateral wall. Early results are better with PFNA2 however both methods yield similar results in terms of fracture healing and functional outcomes after the last follow-up. There were no statistically significant differences in complications. We conclude that the use of the PFNA2 internal fixation technique has the advantage of less trauma in elderly patients than the 95-degree condylar blade plate.

Conflicts of Interest

The authors declare that they have no conflict of interest.

Ethical Committee Approval

Consent for publication. Authors provide formal written consent to publish before submission of the article.

Authors Contribution

All authors have contributed in clinical study and preparation of manuscript.

Compliance with Ethical Standards

All procedures were in accordance with the ethical standards of the institutional and research committee and with the 1964 Helsinki declaration and its later amendments or comparable ethical standards.

Informed consent was obtained from all individual participants included in the study.

References

- [1] Dobbs, R.E., Parvizi, J. and Lewallen, D.G. (2005) Perioperative Morbidity and 30-Day Mortality after Intertrochanteric Hip Fractures Treated by Internal Fixation or Arthroplasty. *The Journal of Arthroplasty*, **20**, 963-966.
<https://doi.org/10.1016/j.arth.2005.04.035>

- [2] Cheng, C.L., Chow, S.P., Pun, W.K. and Leong, J.C.Y. (1989) Long-Term Results and Complications of Cement Augmentation in the Treatment of Unstable Trochanteric Fractures. *Injury*, **20**, 134-138. [https://doi.org/10.1016/0020-1383\(89\)90082-X](https://doi.org/10.1016/0020-1383(89)90082-X)
- [3] Audigé, L., Hanson, B. and Swiontkowski, M.F. (2003) Implant-Related Complications in the Treatment of Unstable Intertrochanteric Fractures: Meta-Analysis of Dynamic Screw-Plate versus Dynamic Screw-Intramedullary Nail Devices. *International Orthopaedics*, **27**, 197-203. <https://doi.org/10.1007/s00264-003-0457-6>
- [4] Fogagnolo, F., Kfuri, M. and Paccola, C.A.J. (2003) Intramedullary Fixation of Per-trochanteric Hip Fractures with the Short AO-ASIF Proximal Femoral Nail. *Archives of Orthopaedic and Trauma Surgery*, **124**, 31-37. <https://doi.org/10.1007/s00402-003-0586-9>
- [5] Duymus, T.M., Aydogmus, S., Ulusoy, I., et al. (2019) Comparison of Intra- and Extramedullary Implants in Treatment of Unstable Intertrochanteric Fractures. *Journal of Clinical Orthopaedics & Trauma*, **10**, 290-295. <https://doi.org/10.1016/j.jcot.2018.04.003>
- [6] Gadegone, W.M. and Salphale, Y.S. (2007) Proximal Femoral Nail—An Analysis of 100 Cases of Proximal Femoral Fractures with an Average Follow up of 1 Year. *International Orthopaedics*, **31**, 403-408. <https://doi.org/10.1007/s00264-006-0170-3>
- [7] Jamshad, O.P., Mathew, J. and Karuppall, R. (2021) Functional and Radiological Outcome of Unstable Intertrochanteric Fracture in Old Age Treated with Proximal Femoral Nail Antirotation-2. *Journal of Clinical & Diagnostic Research*, **15**, 5-7. <https://doi.org/10.7860/JCDR/2021/47653.14751>
- [8] Suriyajakuthana, W. (2004) Intertrochanteric Fractures of the Femur: Results of Treatment with 95 Degrees Condylar Blade Plate. *Journal of the Medical Association of Thailand*, **87**, 1431-1438.
- [9] Mahomed, N.N., Arndt, D.C., McGrory, B.J. and Harris, W.H. (2001) The Harris Hip Score: Comparison of Patient Self-Report with Surgeon Assessment. *The Journal of Arthroplasty*, **16**, 575-580. <https://doi.org/10.1054/arth.2001.23716>
- [10] Kyle, R., Gustilo, R. and Premer, R. (1979) Analysis of Six Hundred and Twenty-Two Intertrochanteric Hip Fractures. *Orthopedic Trauma Directions*, **8**, 25-29. <https://doi.org/10.1055/s-0030-1267060>
- [11] Ranjan, R., Kumar, R. and Singh, A. (2017) Functional Outcome of Patients Treated with Proximal Femoral Nail for Unstable Trochanteric Fractures. *International Journal of Orthopaedics Sciences*, **3**, 349-351. <https://doi.org/10.22271/ortho.2017.v3.i4e.48>
- [12] Janardhan, P.T. and Japatti, M.S. (2021) Comparative Study of Efficiency of PFN vs PFNA-II (Asian) in Intertrochanteric Femur Fracture with Deficient Lateral Wall—A Prospective Interventional Study. *National Journal of Clinical Orthopaedics*, **5**, 114-117. <https://doi.org/10.33545/orthor.2021.v5.i1b.305>
- [13] Yong, C.K., et al. (2009) Dynamic Hip Screw Compared to Condylar Blade Plate in the Treatment of Unstable Fragility Intertrochanteric Fractures. *Malaysian Orthopaedic Journal*, **3**, 13-18. <https://doi.org/10.5704/MOJ.0905.001>
- [14] Fan, J., Xu, X., Zhou, F., et al. (2021) Risk Factors for Implant Failure of Intertrochanteric Fractures with Lateral Femoral Wall Fracture after Intramedullary Nail Fixation. *Injury*, **52**, 3397-3403. <https://doi.org/10.1016/j.injury.2021.07.025>
- [15] Jain, S., Dawar, H., Khare, H., Kumar, M. and Ajmera, A. (2022) Does Augmentation of Intramedullary Nails by a Buttress Plate Effectively Restore Lateral Wall Integrity in Intertrochanteric Fractures. *International Orthopaedics*, **46**, 2365-2371.

- <https://doi.org/10.1007/s00264-022-05488-w>
- [16] Gadegone, W.M., Shivashankar, B., Lokhande, V. and Salphale, Y. (2017) Augmentation of Proximal Femoral Nail in Unstable Trochanteric Fractures. *SICOT-J*, **3**, 12-18. <https://doi.org/10.1051/sicotj/2016052>
- [17] Kulkarni, S.G., Babhulkar, S.S., Kulkarni, S.M., Kulkarni, G.S., Kulkarni, M.S. and Patil, R. (2017) Augmentation of Intramedullary Nailing in Unstable Intertrochanteric Fractures Using Cerclage Wire and Lag Screws: A Comparative Study. *Injury*, **48**, S18-S22. [https://doi.org/10.1016/S0020-1383\(17\)30489-8](https://doi.org/10.1016/S0020-1383(17)30489-8)
- [18] Gupta, R.K., Sangwan, K., Kamboj, P., Punia, S.S. and Walecha, P. (2010) Unstable Trochanteric Fractures: The Role of Lateral Wall Reconstruction. *International Orthopaedics*, **34**, 125-129. <https://doi.org/10.1007/s00264-009-0744-y>
- [19] Purushotham, V.J., Khan, M.A. and Kumar, N. (2020) Efficacy of Proximal Femoral Nail Augmentation in Unstable Intertrochanteric Fracture. *International Journal of Research in Orthopaedics*, **6**, 1043-1049. <https://doi.org/10.18203/issn.2455-4510.IntJResOrthop20203729>
- [20] Zhang, W.Q., Sun, J., Liu, C.Y., Zhao, H.Y. and Sun, Y.F. (2018) Comparing the Intramedullary Nail and Extramedullary Fixation in Treatment of Unstable Intertrochanteric Fractures. *Scientific Reports*, **8**, Article No. 2321. <https://doi.org/10.1038/s41598-018-20717-2>
- [21] Haidukewych, G.J., Israel, T.A. and Berry, D.J. (2001) Reverse Obliquity Fractures of the Intertrochanteric Region of the Femur. *The Journal of Bone and Joint Surgery. American Volume*, **83**, 643-650. <https://doi.org/10.2106/00004623-200105000-00001>
- [22] Mallya, S., et al. (2019) Comparison of Radiological and Functional Outcome of Unstable Intertrochanteric Femur Fractures Treated Using PFN and PFNA-2 in Patients with Osteoporosis. *European Journal of Orthopaedic Surgery & Traumatology*, **29**, 1035-1042. <https://doi.org/10.1007/s00590-019-02401-x>
- [23] Gotfried, Y. (2004) The Lateral Trochanteric Wall: A Key Element in the Reconstruction of Unstable Pertrochanteric Hip Fractures. *Clinical Orthopaedics and Related Research*, **425**, 82-86. <https://doi.org/10.1097/01.blo.0000132264.14046.c2>
- [24] Arya, S., Arun, H.S., Rawat, S.S. and Sankar, S. (2020) Clinical Study of Fixation of Unstable Inter-Trochanteric Femoral Fractures with 95° Angle Blade Plate. *International Journal of Orthopaedics Sciences*, **6**, 606-610. <https://doi.org/10.22271/ortho.2020.v6.i2j.2108>