



Angiographic Study of the Anatomical Variations of the Anterior Communicating Artery Complex

Mohamed Ali Eissa^{1*}, Ahmed Ganna¹, Mohamed Amer¹ and Ahmed Shakal¹

¹Department of Neurosurgery, Tanta University, Egypt.

Authors' contributions

This work was carried out in collaboration among all authors. Author MAE designed the study, performed the statistical analysis, wrote the protocol and wrote the first draft of the manuscript. Authors AG and MA managed the analyses of the study. Author AS managed the literature searches. All authors read and approved the final manuscript.

Article Information

DOI: 10.9734/JAMMR/2020/v32i2030688

Editor(s):

(1) Dr. Ashish Anand, GV Montgomery Veteran Affairs Medical Center, University of Mississippi Medical Center & William Carey School of Osteopathic Medicine, USA.

Reviewers:

(1) Josué Martos, University Federal of Pelotas, Brazil.

(2) Milena Trandafilovic, University of Nis, Serbia.

Complete Peer review History: <http://www.sdiarticle4.com/review-history/62628>

Original Research Article

Received 28 August 2020

Accepted 05 November 2020

Published 11 November 2020

ABSTRACT

Introduction: The anterior communicating artery complex consists of two anterior cerebral arteries (ACA), the anterior communicating artery (AComA) and the recurrent arteries of Heubner. ACA is divided into the three segments; A1 originating from the internal carotid artery, A2 extending from AComA and A3 also known as the pericallosal artery. The anatomical variations of the ACoA complex are not adequately discussed. The aim of this study is to detect the anatomical variations in the ACoA complex in patients that don't have any intracranial vascular pathology.

Aims: The present study determines the anatomical Variations of the anterior communicating artery complex.

Patients and Methods: The study group consists of 70 subjects, using Digital Subtraction Angiography and Computed Tomography Angiography to visualize the vascular anatomy.

Results: About 14.29% (10 patients) Aplastic ACoA, 7.14% (5 patients) have unilateral A1 ACA segment hypoplasia, 2.86% (2 patients) have unilateral A1 ACA segment aplasia.

Conclusion: The most common anatomical variant is Aplastic ACoA.

Keywords: Anatomical variations; anterior communicating artery complex.

*Corresponding author: E-mail: ma5701444@gmail.com;

1. INTRODUCTION

Intracranial arterial anatomical vascular variations are very common findings in the general population. Study of the vascular variations has a clinical impact because these variants have a big role in development of intracranial aneurysms [1]. The anterior communicating artery complex is composed of two anterior cerebral arteries (ACA), the anterior communicating artery and the recurrent arteries of Heubner. ACA is divided into three segments; A1 origins from the internal carotid artery to the ACoA, A2 starting from AComA to the origin of callosal-marginal artery and A3 is also named the pericallosal artery [2]. Based on the anatomical and radiological studies, less than 50% of the general population has complete Circle of Willis. Vascular variances include hypoplasia and aplasia [3]. The most common site of the intracranial aneurysms is the ACoA. Anatomical variations in the anterior communicating artery complex might promote stronger hemodynamic changes therefore endorses the formation of an intracranial aneurysm [4]. Many studies found that A1 ACA segment anomalies as the most common variant. There are several methods to identify the anatomical variations in ACoA complex such as digital subtraction angiography (DSA), computed tomography (CT) angiography, magnetic resonance angiography (MRA), and intraoperative findings [5]. The present study determines the anatomical Variations of the anterior communicating artery complex.

2. PATIENTS AND METHODS

The study group consisted of 70 patients who underwent angiographic study which revealed no vascular pathology. The indication of angiographic study in these patients included patients with head trauma, patients with severe headache and normal CT brain, patients with intracranial pathologies (such as tumors, intracerebral hematoma and subarachnoid hemorrhage with CTA and DSA showing no intracranial aneurysms or AVMs) other than any vascular pathology as cerebral aneurysm and AVMs.

2.1 Imaging and Analysis

CTA images were acquired using Toshiba Aquilion one (RAD-CT1) with software version / V.0.6, while in DSA, we used Toshiba Infx 8000c, japan, code 5, using the following study parameters — exposure: 120 kV, 74 mA, 120

mAs; rotation time: 0.75; slice thickness: 3 mm; pitch:

1.5. Patients were injected intravenously with an iodine contrast medium (Ultravist, Omnipaque) to achieve angiographic images. The collected date was examined and the width of the bilateral A1 segments was measured immediately after the take-off from the terminus of the internal carotid artery. We carefully examined each part of the AComA complex and then measured the internal diameter of each artery. Arterial segments that were measured less than 1 mm in diameter were classified as hypoplastic.

2.2 Anterior Communicating Artery Complex Variants

The AComA complex variations is categorized into 10 following types: 1 — typical configuration, 2 — hypoplastic AComA, 3 — aplastic AComA, 4 — unilateral A1 segment of the anterior cerebral artery (ACA) hypoplasia, 5 — unilateral A1 segment of the ACA aplasia, 6 — common trunk of ACA with absence of AComA, 7 — presence of a third A2 ACA segment (median artery of corpus callosum), 8 — unilateral hypoplasia of A1 ACA segment and A2 ACA segment (bihemispheric ACA), 9 — unilateral A2 ACA segment aplasia (azygos ACA), 10 — duplicated AComA [4].

3. RESULTS

The study group consists of 42 females and 28 males (mean age \pm SD 47.986 \pm 13.530). It consists of 49 patients (70 %) had Typical configuration, 14.29% (10 patients) had Aplastic AComA, 7.14% (5 patients) had unilateral A1 ACA segment hypoplasia, 2.86% (2 patients) had unilateral A1 ACA segment aplasia, 4.29 (3 patients) had Common trunk of ACA with absence of AComA, 1.43% (1 patient) had Unilateral A2 ACA segment aplasia (Azygos ACA).

The statistical analysis of the findings showed that there is no significant difference in the anatomical variations of AComA complex among both genders (Table 2).

4. DISCUSSION

The aim of this study was to detect the anatomical variations in the ACoA complex in patients with no intracranial vascular pathology.

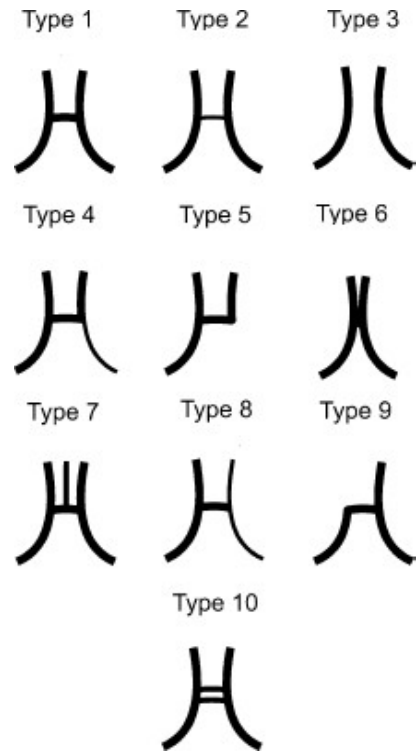


Fig. 1. Types of anatomical variations of ACoA complex [4]

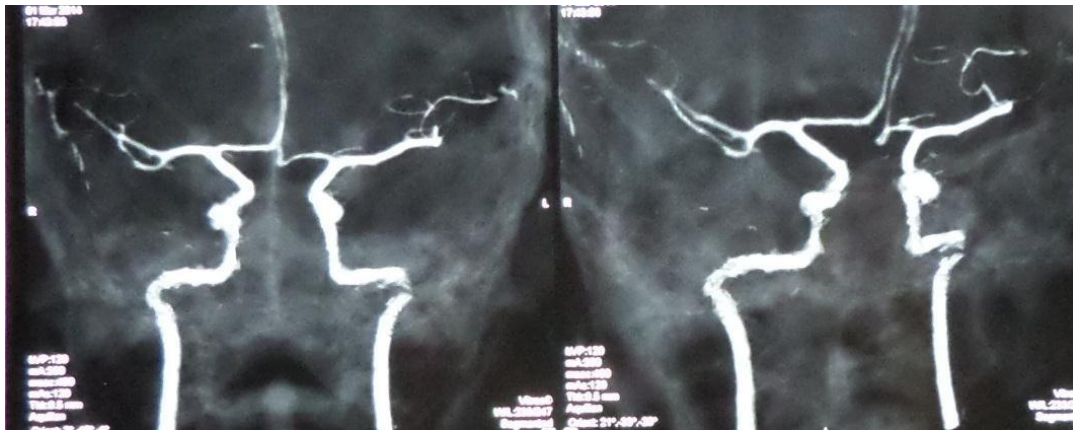

Fig. 2. CT angiography showing a case of aplastic ACoA complex, representing the most common variant of ACoA complex

In our study, we used both DSA and CT angiography to study the anterior communicating artery complex and to detect the anatomical variations. The use of both DSA and CTA gives more accurate results. All the 70 patients have done CTA; only 40 patients have done DSA.

In contrast to other studies which used only one single imaging method as Agayev K, et al. [6], who used DSA only in his study to detect the

anatomical variations of AcomA complex, while Kasuya H, et al. [7] used only CT angiography as the imaging method, while Akira Uchino A, et al. [8], used MR angiography to study the AComA complex.

CT angiography (CTA) is a noninvasive imaging technique. Images can be safely obtained by a trained technologist without the need for arterial puncture or catheter manipulation. CTA is not

Table 1. The distribution of the anatomical variations of the AComA complex in the study group

Type	Group II	
	N	%
Typical configuration	49	70.00
Hypoplastic AComA	0	0.00
Aplastic AComA	10	14.29
Unilateral A1 ACA segment hypoplasia	5	7.14
Unilateral A1 ACA segment aplasia	2	2.86
Common trunk of ACA with absence of AComA	3	4.29
Presence of a third A2 ACA segment (median artery of corpus callosum)	0	0.00
Unilateral hypoplasia of A1 ACA segment and A2 ACA segment	0	0.00
Unilateral A2 ACA segment aplasia (Azygos ACA)	1	1.43
Duplicated AComA	0	0.00
Total	70	100.00

Table 2. The relation between the anatomical variations of AComA complex and the gender of the patients

Type Group II	Sex						Chi-Square	
	Male		Female		Total		χ^2	P-value
	N	%	N	%	N	%		
Typical configuration	19	69.15	30	71.43	49	70.00	0.003	0.958
Aplastic AComA	4	13.00	6	15.09	10	14.29	0.122	0.727
Unilateral A1 ACA segment hypoplasia	2	7.14	3	7.30	5	7.14	0.224	0.636
Unilateral A1 ACA segment aplasia	1	3.57	1	2.30	2	2.86	0.193	0.660
Common trunk of ACA with absence of AComA	2	7.14	1	2.30	3	4.29	0.131	0.718
Unilateral A2 ACA segment aplasia (Azygos ACA)	0	0.00	1	2.30	1	1.43	0.042	0.837
Total	28	100.00	42	100.00	70	100.00	-	-

associated with significant patient risks. Furthermore, CTA image acquisition requires an imaging time of 1 minute, while for the seek of higher resolution images, DSA was done either as a confirmatory radiological investigation or as diagnostic angiography before therapeutic endovascular coiling of the aneurysm.

We found in our study that the typical variant of the ACoA complex represents 70 % of the patients, while the most common anatomical variant was aplastic AComA with 14.29 %, followed by unilateral A1 ACA segment hypoplasia with 7.14 %, then common trunk of ACA with absence of AComA with 4.29 %, then unilateral A1 ACA segment aplasia with 2.86 %, then unilateral A2 ACA segment aplasia (Azygos ACA) with 1.43%.

Kransy A, et al. [9], studied the anatomical variations of ACoA in patients without any intracranial pathologies and found that the typical

variant represents 52.55% while the most common anatomical variation is aplastic AComA (19.57%) followed by A1 segment unilateral hypoplasia with 7.30%, then common trunk of ACA with absence of ACoA with 6.33%, then hypoplastic AComA with 5.35%, then unilateral A1 ACA segment aplasia with 4.62%, then unilateral A2 ACA segment aplasia (azygos ACA) with 0.73%, while Polak J, et al. [10], found that 80% of the control group showed typical configuration of the AComA complex, while Aplastic AComA and Unilateral hypoplasia of A1 segment were the most common anatomical variants and showed equal prevalence of 7% each, while unilateral aplasia of A1 segment represented 6 % of his control group.

5. CONCLUSION

In our study the most common anatomical variant in ACoA complex is Aplastic ACoA. It must be noted that the statistical significance of this

finding was not completely confirmed due to a relatively small study population which was conducted in our study.

CONSENT AND ETHICAL APPROVAL

As per international standard or university standard guideline participant consent and ethical approval has been collected and preserved by the authors.

COMPETING INTERESTS

Authors have declared that no competing interests exist.

REFERENCES

1. Kovač JD, Stankovid A, Stankovid D, Kovač B, Šaranovid D. Intracranial arterial variations: A comprehensive evaluation using CT angiography. Medical Science monitor: International Medical Journal of Experimental and Clinical Research. 2014; 20:420.
2. Krzyżewski R, Tomaszewska I, Lorenc N, Kochana M, Goncerz G, Klimek-Piotrowska W, et al. Variations of the anterior communicating artery complex and occurrence of anterior communicating artery aneurysm: A2 segment consideration; 2014.
3. Fattahian R, Gorji RA, Sadeghi M, Bagheri SR. Assessment of the prevalence of vascular anomalies of the circle of willis based on the autopsy of cadavers in kurdish race between 2016 and 2017. Materia Socio-Medica. 2018;30(3):189.
4. Fattahian R, Gorji RA, Sadeghi M, Bagheri SR. Assessment of the prevalence of vascular anomalies of the circle of willis based on the autopsy of cadavers in kurdish race between 2016 and 2017. Materia Socio-Medica. 2018;30(3):189.
5. Yilmaz A, Özkul A. Anatomical variations of anterior circulation in the brains of patients with and without intracranial aneurysm. Turkish Journal of Cerebrovascular Diseases. 2018;24(1): 8-13.
6. Agayev K, Onal B, Yavuz K. et al. The association of A1 segment hypoplasia/aplasia with anterior communicating artery aneurysm: A radiological study. Turk Neurosurg. 2005; 15:196.
7. Kasuya H, Shimizu T, Nakaya K, Sasahara A, Hori T, Takakura K. Angles between A1 and A2 segments of the anterior cerebral artery visualized by three-dimensional computed tomographic angiography and association of anterior communicating artery aneurysms. Neurosurgery. 1999;45(1):89-94.
8. Uchino A, Nomiyama K, Takase Y, Kudo S. Anterior cerebral artery variations detected by MR angiography. Neuroradiology. 2006;48(9):647-52.
9. Krasny A, Nensa F, Sandalcioglu IE, Görlicke SL, Wanke I, Gramsch C, et al. Association of aneurysms and variation of the A1 segment. Journal of NeuroInterventional Surgery. 2014;6(3): 178-83.
10. Polak J, Ciuk S, Kucybała I, Giliavas J, Gajdosz A, Urbanik A. Cerebral aneurysms: Are they associated with anatomic variations of carotid and main cerebral arteries? World neurosurgery. 2019;124:604-8.

© 2020 Eissa et al.; This is an Open Access article distributed under the terms of the Creative Commons Attribution License (<http://creativecommons.org/licenses/by/4.0>), which permits unrestricted use, distribution, and reproduction in any medium, provided the original work is properly cited.

Peer-review history:

*The peer review history for this paper can be accessed here:
<http://www.sdiarticle4.com/review-history/62628>*